
STEREOTACTIC CORE NEEDLE BIOPSY IN DIAGNOSIS OF NON PALPABLE BREAST LESIONS

Gihan Hassan Gamal¹ and Hanan Soliman Gewefel²

Radiology Department, 6 Oct. University Hospital¹ and Misr University Hospital²

ABSTRACT

Background: Stereotactic core biopsy is becoming increasingly popular as a technique which provides a histological diagnosis for mammographic abnormalities while avoiding the trauma, deformity and scarring breast on follow up mammograms. The materials used were, a special digital mammography machine which produces images of the breast that can be immediately seen on a computer screen, and the use of a large hollow needle to remove one sample of breast tissue per insertion. **The aim of this study:** is to assess the accuracy and reliability of stereotactic core needle breast biopsy (SCNBB) in mammographically detected nonpalpable lesions and to develop a protocol for follow up program (Duijm et al.: 2007). **Subjects and Methods:** This study was performed over a period of two years. 30 women with average age of 46 years (22-74) were included in this study. Their mammograms showed radiological abnormality as follow: Microcalcification in 13 cases, distortion in the structure of breast tissue in seven cases, an area of abnormal tissue changes in five cases, non palpable suspicious small solid mass in four cases, tiny cluster of small calcium deposits at a previous surgery site in one case. Clinical breast examination for all women revealed no palpable mass. Stereotactic breast biopsy was performed for all women. **Results:** out the (30) stereotactic core biopsies, (19) cases showed a benign process: fat necrosis in (3) samples, sclerosing adenosis in (6) cases, dystrophic calcification in (4) cases, ductal hyperplasia in (4) cases, one case of duct papilloma and one case of fibrosis scar. Positive biopsy samples for malignancy were (11) cases. Ductal carcinoma in situ in (3), invasive carcinoma in (3) and atypical ductal hyperplasia

in five cases. All malignant cases were confirmed at subsequent excision biopsy. All benign cases were assigned to follow up mammographic protocol every 6 months up to two years. **Conclusion:** with the increasing use of screening mammography, more and more non –palpable lesion are found. Stereotactic core breast biopsy based on its excellent accuracy and excellent tolerance in addition of being minimally invasive, becoming the technique of choice and can replace excision biopsy for the diagnosis of non-palpable breast lesions.

INTRODUCTION

Breast cancer is the second most common malignancy of woman. Survival rates depend on the stage of diagnosis. Woman diagnosed with early stages of breast cancer have a 5-years survival rate near 100%. However, early breast cancer is asymptomatic, and the only way to detect it is by population-wide screening programs that include regular mammography and physical examination.

The establishment of national breast-screening programs in Europe And North America has led to an increase in the detection of small or impalpable breast lesions. The ability to achieve an accurate histopathologic diagnosis of these lesions is crucial to any screening program in terms of appropriate treatment planning and patient counseling.

Although mammography is frequently described as a diagnostic test, mammography is primarily a screening test. Despite its ability to find earlier stage, clinically occult cancer, it is not able to permit the differentiation of benign findings from malignant, because the morphologic characteristics of benign and malignant lesions may be similar. (Liefland et al: 2004)

Stereotactic breast needle biopsy refers to , the sampling of nonpalpable or indistinct breast lesions by using techniques that enable the spatial localization

of the lesion within the breast .Stereotactic techniques have evolved in parallel with the trend in breast conservation and minimally invasive surgery.

During stereo imaging, two-dimensional digital images of breast are taken from two different angles. Both images are sent to a computer for image analysis. The computer compares the data from each image and calculates the three-dimensional location coordinates for breast abnormality. With such precise information to guide the biopsy needle, and can accurately sample fluid or tissue. (Hatmaker et al: 2006)

In the past, impalpable breast lesions would have been surgically excised after needle localization, resulting in a vast number of surgeries for nonmalignant mammographic abnormalities. In the United States, it is estimated that more than a million surgical breast biopsies are performed , and in only 15-30% the samples subsequently found to be malignant. (Karen et al: 2010)

Compared with open surgical biopsy, needle in stereotactic biopsy causes less trauma and disfigurement and is performed as an outpatient procedure with the patient under local anesthetic. Stereotactic needle biopsy is an important tool in the diagnosis of breast lesions as part of the triple assessment, which includes, clinical, radiologic and cytohistopathologic studies. Definitively diagnosing these lesions with needle biopsy has several advantages. For benign lesions, establishing a definitive diagnosis obviates unnecessary surgical excision or protracted follow up, both of which are costly in psychosocial and resource terms. A definitive diagnosis of cancer allows the patients to make an informed choice and to obtain counseling before surgery. It is also facilitate in the planning of multimodal treatment in terms of neoadjuvant chemotherapy, the type of procedure and early or delayed reconstruction (Hemant et al 2011).

SUBJECT AND METHODS

This study was carried over a period of two years (from October 2009 to December (2011), at Sheikh Zayed specialized Hospital and a special private women health centre. (30) Women were included in this study, with average age of 46 years (22-74) and were chosen from (500) women screening program. All women were asymptomatic except three cases, were complaining of breast problems as breast pain, or nipple discharge, and one had history of previous excision biopsy. Clinical breast examination for all cases revealed no palpable mass. Their mammograms showed radiological abnormality as follow: microcalcification in (13) breasts, distortion in the structure of breast tissue in (7) breasts, an area of abnormal tissue changes in (5) breasts, non palpable small solid mass in (4) breasts, tiny cluster of calcium deposits at a previous surgery site in (one) case. Stereotactic breast biopsy was performed for all women after their agreement

The special mammography unit used to perform the stereotactic biopsy is a digital mammography machine, which means that the films are replaced by electronic detectors, change the x rays into electric signals, which are used to produce images of breast that can be seen on a computer screen, the machine has special accessories that allow only the breast to be exposed to the x- rays, the principle of stereotactic imaging is to take two images of the diseased breast from two different angles , and sent to the computer for image analysis , the computer will compare the data from each image and calculate the 3D location coordinates for the breast abnormalities with such precise information to guide biopsy needle accurately to the target and remove sample of abnormal tissue.

The procedure followed in our study:

The breast was compressed to keep the breast still throughout the procedure, several breast images were taken for the diseased breast, local anesthetic was injected into the breast, and small cut was made in the breast at the site of needle puncture, the needle (14 or 16 gauges) then introduced and advanced to the location

of the abnormal tissue. Stereotactic images then repeated to confirm that the needle is in the right place. A core of abnormal tissue then removed and after the completion of sampling the needle was removed and compression was applied at the biopsy site to prevent hematoma formation, the opening in the skin was covered with sterile dressing.

RESULTS

The histological results of (30) stereotactic mammographic breast biopsies revealed:

That (11) of them showed malignant process (36, 6 %) and (19 cases) showed benign process (63.3%). The malignant biopsies were as follow: ductal carcinoma in situ in three cases (27, 2%), atypical ductal hyperplasia in five cases (45.4%) and advanced carcinoma in three (27.2%). All cases had confirmation on subsequent surgical excision.

The benign biopsies were as follow:

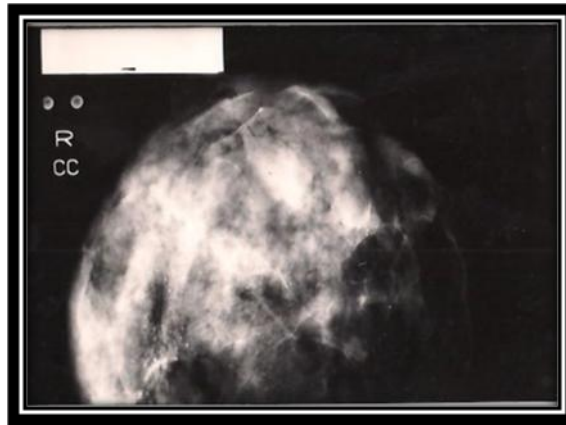
Fat necrosis in three samples (15.7 %), sclerosing adenosis in six cases (31.5%), dystrophic calcification was proved in four samples (21%), duct papilloma in one case (5.2 %), one sample (5.2 %) was diagnosed as fibrosis scar and four cases of ductal hyperplasia (21%) .One case with ductal hyperplasia on core biopsy, was considered not to correlate with the radiological abnormality , and excision biopsy was advised and proved to be ductal carcinoma in situ .Patients diagnosed with benign process on core biopsy had been followed for two years by the stander follow up mammogram protocol , and no malignant changes could be found, except on case, during the initial 18 months after the follow up protocol was activated, her postbiopsied mammography revealed malignant changes . This underestimation of SCNB diagnosis was due to the presence of dense microcalcification in the lesion which was responsible for insufficient material obtained for histological assessment. Excision biopsy was advised and proved malignancy. From the above results we proved that the sensitivity rate of stereotactic core biopsy for malignant processed was 100%. And for benign

processes was (89.4 to 90%). Unfortunately, a significant number may have relatively advanced malignancy when first seen, despite having nonpalpable breast disease. The mammographic findings with high rate of malignancy in our work were microcalcification followed by those had distorted breast tissue, and the underestimation of the technique was in case of local distorted breast tissue with microcalcification. But in general stereotactic breast biopsy is non invasive, quick with short recovery time, less expensive than open surgical biopsy, well tolerated by all patients not painful and with low risk of infection or bleeding.

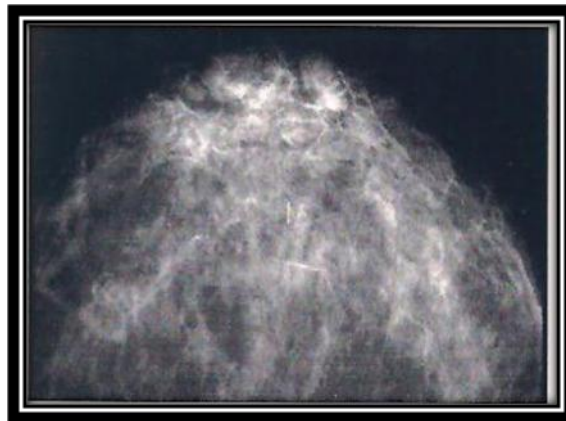Follow up information was obtained from mammogram reports, and were reviewed for any suspicious change in the original lesion that might require repeat biopsy. Our mammogram follow up recommendation after benign SCNB was 6 month interval mammography up to two years. Stability at this point usually resulted in the return of the patient to routine clinical evaluation and appropriate mammographic screening. The follow up was divided into 6 month intervals to determine when a mammographic change occurred. Rebiopsy was performed using SCNB.

Pathology reported from rebiopsied lesions were reviewed and checked for concordance with initial benign results or for the presence of malignant pathology. Reports that showed evidence of malignancy at the repeated biopsy were reviewed to determine whether sampling error was responsible for this underestimation, or whether new malignant tissue had developed in the previously biopsied site. In our cases, sampling error was responsible for underestimating one case of local massive distorted tissues with microcalcification. Incomplete follow up at our work, was in two cases, one patient died and the other refused to complete the follow up program.

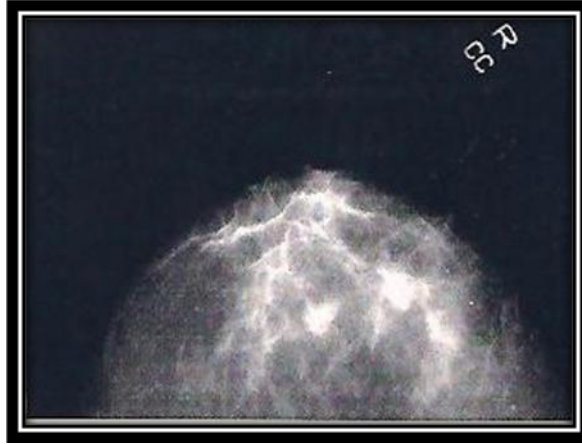
Case Presentation



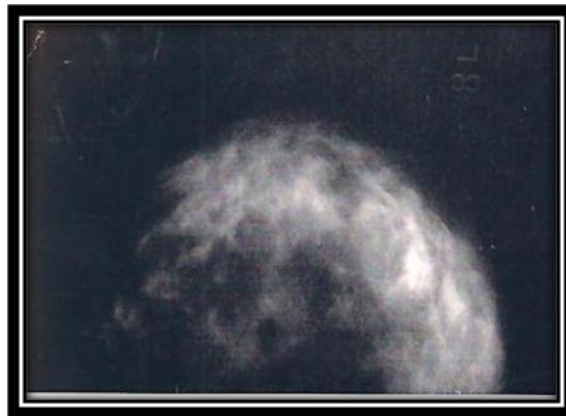Case (1): 50 years old woman presented by breast pain and bleeding per nipple .Clinical examination revealed no palpable breast mass, mammogram showed suspicious tiny micro-calcification .Histologic sample by SCNB proved to be ductal carcinoma



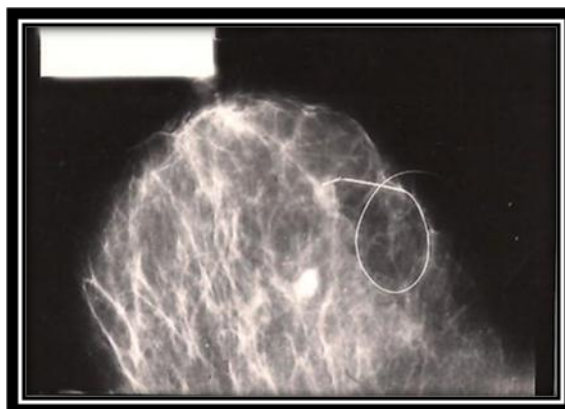
Case (2) 40 years old women presented with nodularity in the left breast , no definite lump .Mammogram showed small densities, stereotatic core needle biopsy and histologic examination revealed ductal papilloma.



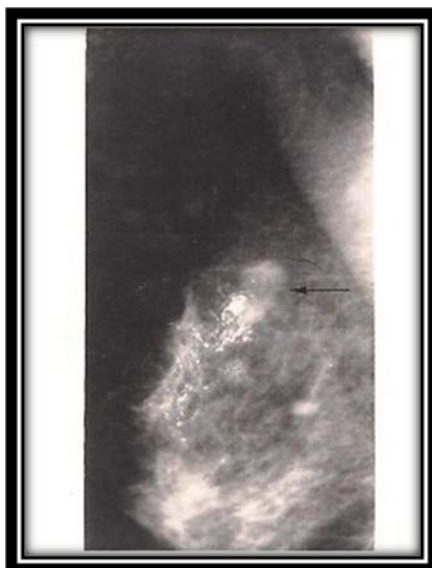Case (3): 22 years women, on clinical examination no palpable mass. The screening mammogram revealed two small densities, ill defined margins but no speculation noted. SCNB revealed sclerosing adenosis.



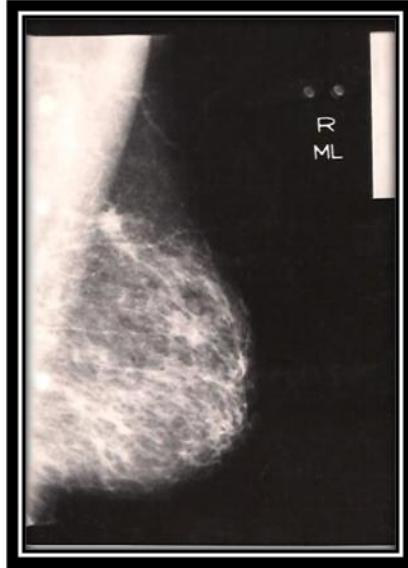Case (4) postmenopausal women presented for screening mammogram showed, an area of distorted breast tissue with no definite mass, or calcification or speculation . Histologic result of SCNB proved to be fat necrosis.



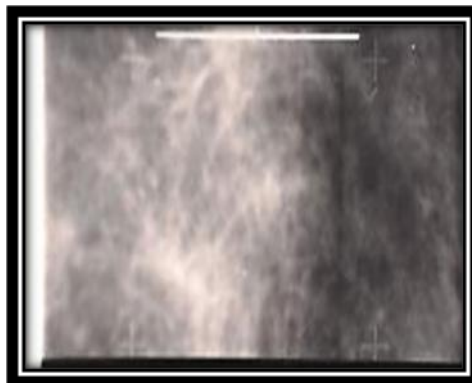
Case (5) 33 years old woman presented by breast pain and nipple discharge, cranio-caudal view of right breast showed retro-areolar densities –no definite mass . SCNB proved Ductasia with atypical ductal hyperplasia.



Case (6) postmenopausal showed punctuate group of benign microcalcification at retro-areolar region and extended deeply to the upper quadrant region of left breast . SCNB histology revealed dystrophic calcification at the site of prior lumpectomy .



Case (7): Woman of 46 years old, mammogram revealed distorted breast parenchyma with microcalcification no definite mass. Histology of SCNB revealed ductal carcinoma grade II.



Case (8) Woman of 50 years old , on mammogram , local distorted breast tissues noted , no calcification or mass seen . SCNB was done and histology revealed fat necrosis.

DISCUSSION

Ciatto et al: 2007 stated that the primary goal of initial biopsy of any abnormality is to diagnose the abnormality as benign or malignant .Generally, only malignant lesions require invasive follow up procedures such as surgical excision , but the majority of women who are sent for breast biopsy do not have malignant lesions and do not require follow up surgery . Women who are diagnosed as malignant lesions by open surgical biopsy are often subject to an additional surgical procedure to ensure the lesion has been completely removed and in some cases for lymph node evaluation. Thus an accurate initial core –needle biopsy would in most cases allow women to avoid any open surgical procedure.

Fajardo et al: 2004 stated that patients with atypical ductal hyperplasia, atypical lobular hyperplasia, or lobular neoplasia on core needle biopsy should underwent surgical excision. Those with negative core biopsy but Suspicious (discordant) pre-biopsy mammography , also underwent surgical biopsy .Patients having a negative core biopsy that was concordant with the pre-biopsy mammography suspicious , were assigned to follow up mammography at 6,12. and 24 months following core biopsy.

Hemant : 2011 stated that the main indication of stereotactic needle biopsy is in sampling nonpalpable breast lesions. It also has an important role in the biopsy of small, indistinct lesions, particularly those occurring in association with surgical scarring, fibrosis, or prosthetic implant. A further indication is for repeat biopsy in cases in which previous biopsy results are inconclusive .This situation often occurs when the tumor has both benign and malignant or preinvasive components.

Ciatto et al: 2007 stated that Potential advantages of SCNB technique include lower cost, less trauma to the patient , and the absence of cosmetic deformity of the breast and scarring on follow up mammograms , its limitations are in cases of massive and diffuse calcium deposits scattered throughout the breast , or lesions

near chest wall . So if tissue obtained by SCNB does not correlate with pre- biopsy mammographic abnormality, excisional biopsy should be performed..

Phillip Burns et al: 2000 stated that SCNB is an alternative to open biopsy and show the reliability of this technique when benign pathology is obtained .However, given the possibility of sampling error and the nature of breast disease , close mammographic and clinical follow up is necessary. Our study agree with this opinion where, we followed up our cases with standard mammogram examination after benign results of SCNB ,6 months by unilateral mammography followed by a bilateral mammographic examination at 12 and 24 months.

Hoomtc et al: 2003 concluded that SCNB is enough for correct diagnosis in masses, architectural distortions or stellate lesions without microcalcifications , and in microcalcifications and a mass, but was not sufficient in microcalcifications only.

Roger et al: 2001 stated that stereotactic core biopsy underestimations were 1.9 times more frequent with masses than with calcifications, 1.8 times more frequent with large core biopsy than with vacuum assisted biopsy, and 1.5 times more frequent with 10 or fewer specimens per incision than with more than 10 specimens per incision .This results were proved in his study in measuring the effect of biopsy device , probe size mammographic lesion type , lesion size and number of samples obtained per lesion on the ductal carcinoma in situ. He also proved that SCNB is a reliable alternative to excision biopsy and may underestimates tumor grade in invasive ductal carcinoma and may not differentiate between invasive ductal carcinoma and lobular carcinoma. It is recommended that the diagnosis of atypical ductal hyperplasia on stereotatic core biopsy be followed by excision biopsy, as SCNB underestimates the presence of cancer in this group.

Laura Libermant, 2000 stated that core needle biopsy using either stereotatic or ultrasonographic guidance is a reasonable and accurate alternative to surgical biopsy for diagnosis of most nonpalpable breast lesions. An important component of stereotatic core biopsy procedure is the mammographic and pathological

correlation findings to plan optimal patient management. Properly performed imaging- guided core breast biopsy has reduced the morbidity of surgical breast biopsy and the overall cost of breast cancer diagnosis.

SUMMARY AND CONCLUSION

The study was carried on 30 women collected from breast mammogram screening. Their initial mammograms revealed (13) microcalcification. (7) distortion in breast structure, (4) suspicious small masses , (5) cases of an area of breast tissue distortion and one breast showed ,tiny cluster of small calcium deposit at the site of surgical scar .Clinical breast examination for all cases revealed no palpable mass.Stereotatic core needle biopsy (SCNB) was done for all cases. The histological results of the samples revealed : duct carcinoma in situ in (3), invasive carcinoma in (3) and atypical ductal hyperplasia in (5) .It was observed that , the histological malignant results were more in cases shown on initial mammogram microcalcification alone or with small nonpalpable mass , then those shown distortion of breast structure and lastly in those with local area of distortion .The diagnosis was confirmed by the subsequent excisional biopsy .Benign histological samples were found in (19) breast as: fat necrosis in (3) ,Sclerosis adenosis in (6), dystrophic calcification in (4) ,ductal hyperplasia in (4) , duct papilloma in (1) and fibrosis scar in (1).Follow up program for all benign cases was highly significant , we could detected underestimation of (SCNB) in two women during the follow up period , one case of ductal hyperplasia on core biopsy was considered not correlated with the follow up mammograms , the other case was dense distortion of breast structure with microcalcification which was responsible for insufficient material obtained for histological assessment , both cases were referred to open surgical biopsy and malignant process was proved . In conclusion: An accurate initial (SCNB), would in most cases allow women to avoid any open surgical procedures.

REFERENCES

1. Fajardo LL ,Pisano ED ,CaudryDJ . et al Stereotatic biopsy And sonography large core biopsy of nonpalpable breast lesions : Results of radiologic diagnosis oncology group V study . *Acta Radiol* 2004 ,11(3) :293—308
2. Roger J Takman, Fred Burbonk, Steven H Parker , srereotatic core biopsy of nonpalpable lesion : Determiants of ductal carcinoma in situ underestimation rate .*Radio;ogical society of North America (PSNA)journal* 2001 ,218:479—502
3. Karen H Flegty ,Teffery J Flaherty, Ann M Bick . *Word journal of surgical oncology* .2010 ,8:78
4. Hatmaker AR , Donahue RM , Tarpely JL , Pearson AS . cost effect use of breast biopsy techniques in a veterans health care system.*AM J Surg*.2006 ; 192 : 37—41
5. Ciatto S , Houssami N , Ambroggti D et al . Acuracy and underestimation of malignancy of breast core biopsy: Florence experience of over 4000 consecutive biopsies . *Breast Cancer Res Trea* 2007; 101 (3) 291-7
6. Hoomtc L , Peeters PH ,Mali WP , Borel Rinkes IU , SCNB for diagnosis of nonpalpable lesion reliable without additional excision biopsy .*Ned Tijdschr Geneesk* 2003; 147 (18):868 –73.
7. Duijm LM , Groenwound JH , Plaisier ML ,Fracheboud J. A decade of breast cancer screening in the Neatherlands: trends in the preoperative diagnosis of breast cancer 2007 ; 106 (1):113-9
8. K Liefland H, Lundquist U, Largerestedt and G Svane. Stereotatic core needle biopsy in nonpalpable breast lesion 2004; (45):142-147.
9. R. Phillip Burns. Stereotatic core needle biopsy by surgeons. *Annals of surgeon*. 2000; (4):542-548.
10. Hemant Singhal. Stereotatic core needle biopsy versus fine needle aspiration. *Med Scape*.
11. Laura Libermant .Percutaneous imaging-guided core breast biopsy ,state of Art at the Milleunium ,2000 ; (174) : 1191-119⁹

**التصوير و اخذ عينة باستعمال جهاز الماموجرام الديجيتال ثلاثى الابعاد فى تشخيص اورام
الثدى الغير محسوسة اكلينيكييا
جيهان حسن جمال* وحنان سليمان جويفل**
قسم الاشعة جامعة ٦ اكتوبر* وجامعة مصر****

ان الاكتشاف المبكر لسرطان الثدي يقلل من نسبة الوفاة لهذا المرض ولذلك قامت جمعيات كثيرة لحماية المرأة من هذا المرض بعمل مسح وقائي لتصوير الثدي (ماموجرام) للاكتشاف المبكر لهذا المرض. وقد اجري هذا البحث على عدد ٣٠ سيدة أثبت المسح الوقائي (الماموجرام) وجود تغيرات في أنسجة الثدي، برغم عدم وجود أورام محسوسة بالفحص الاكلينيكي للثدي وكان لا بد من عمل فحص خاص وسهل وسريع بواسطة جهاز ماموجرافي ذو خاصية خاصة يمكنه التصوير (ديجيتال ، ثلاثي الابعاد) للثدي لتحديد مكان الاصابة ثم أخذ عينة في نفس الوقت تحت بنج موضعي.

وهذا الفحص يمكنه تصنيف العينة بدقة عالية هل هي من أنسجة حميدة أو أنسجة من ورم خبيث. واثبت البحث أن هذه الوسيلة السهلة والرخيصة والتي يتم اجراءها في قسم الأشعة هي بنفس الدقة في النتائج التي تم فحصها بواسطة أخذ العينة جراحيا تحت البنج العام. وهذا الفحص لا يستدعي دخول المريضة للمستشفى وليس له مضاعفات كالعلاجات الجراحية مثل الالتهابات والآلام بالاضافة لعدم ترك تليفات في الثدي مكان الجراحة مما يعوق قراءة أي فحص اشعاعي أو غير اشعاعي للثدي في المستقبل. وهذا الفحص أمكننا تجنب أخذ عينات من الثدي جراحيا لعدد كبير من السيدات كما كان يحدث في الماضي ويثبت التحليل أنها اصابات حميدة ولذلك نوصي بعمل هذا الفحص أولا لكل الحالات التي يظهر الفحص الماموجرافي الأولي وجود تغيرات في الثدي وارجاء عمل أخذ العينة جراحيا في حدود ضيقة مثل الاختلاف الشديد والمحسوس بين نوع الاصابة في فيلم الماموجرافي ونتيجة فحص العينة معمليا.